

Newsletter

MONKEYPOX

Compiled by: Prof. E. Vardas Lancet Laboratories South Africa

Monkeypox virus is an enveloped double-strain DNA virus of the Poxviridae family. Orthopoxvirus genus. There are 2 distinct genetic clades, called the Central Africa and West African clades, depending on where they are originally described. The Central African clade causes more severe diseases. Various animal species are the natural hosts of this virus, mainly rodents, tree squirrels and some non-human primates.

- The incubation period ranges from 5- 21 days. Initially the infection (lasting from 0-5 days) is characterized by fever and Lymphadenopathy. The rash or skin eruptions usually occurs 1-3 days after the onset of fever, affecting mainly the face, palms of the hands, soles of the feet, oral mucosa, genitalia and sometimes the conjunctivae.
- The rash is initially maculopapular, then evolves into vesicles and thereafter into pustules which crust over with umbilication and finally desquamation and scarring. In contrast to chickenpox (VZV), the rash of Monkeypox is not painful or itchy and all lesions are in the same stage of evolution.

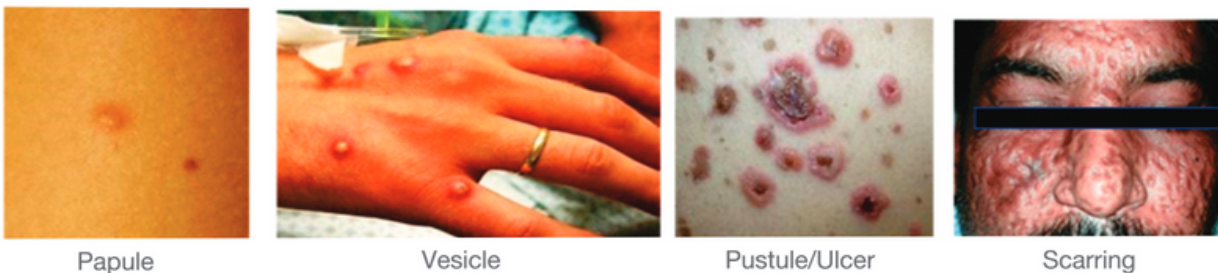
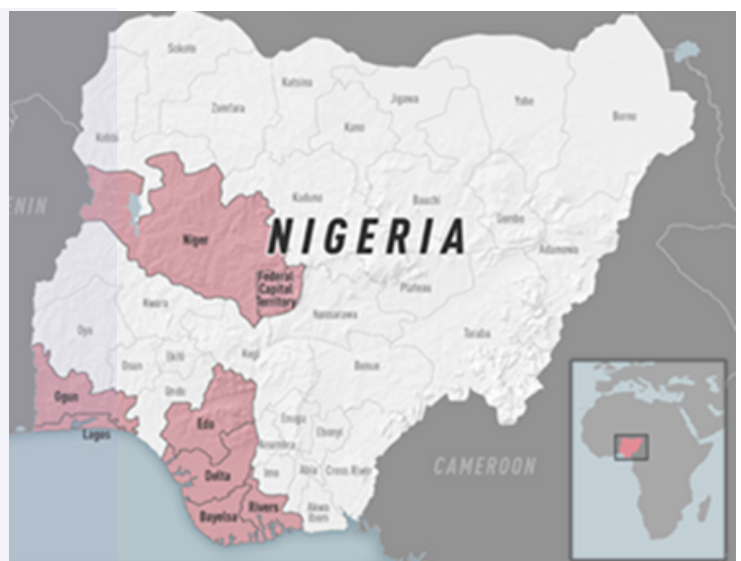

Figure 1. Evolution of the Monkeypox rash

Monkeypox is a self-limiting disease resolving in 2-4 weeks with a low case fatality ratio ranging from 0-11%. Severe disease can occur in young children and those with underlying immune deficiencies from any cause. Vaccination with smallpox vaccine will not have this protection.

Key Facts: Reported cases of Monkeypox in Nigeria

- From September 2017 to the end of April 2022, Nigeria reported a total of **558** suspected cases with **231** (41.4%) confirmed.
- This year, from January 1st to April 30th, we have reported **46 suspected cases** and confirmed **15 from 7 states**. No death has been recorded this year.
- On 26 September 2017, **WHO** was alerted to a suspected outbreak of Monkeypox in Yenagoa, Local Government Area (LGA) in Bayelsa State, Nigeria. The index cluster was reported in a family. All of whom developed similar symptoms of fever and generalized skin rash over a period of four weeks.



- In 2021, cases of Monkeypox have been reported in Nigeria in the following states: **Delta, Lagos, Bayelsa, Rivers, Edo, Federal Capital Territory, Niger, and Ogun.**
- On **May 27, 2022**, the Director-general, NCDC, Dr. Ifedayo Adetifa, disclosed that the Nigeria Centre for Disease Control (NCDC) activated a national multi-sectoral Emergency Operations Centre for Monkeypox (MPX-EOC) at level 2 to strengthen and coordinate ongoing response activities in the country while contributing to the global response.
- Recent cases of Monkeypox have been reported among US travelers returning from Lagos and Ibadan, Nigeria.
- Travelers to Nigeria should avoid contact with **sick people, animals such as rodents (rats, squirrels)** and non-human primates. (monkeys, chimpanzees), products that come from wild animals (including wild game), and contaminated materials (such as clothing or bedding) used by sick people or animals.
- **Seek medical care immediately** if you develop fever, chills, new swollen lymph nodes, and/or new skin rash, and avoid contact with others. If possible, call ahead before going to a healthcare facility.
- Delay travel by public transportation until you have been cleared by a healthcare provider or public health officials.

Transmission

The current outbreak is extraordinary because the first reports were from the UK on 7 May 2022, and to date there have been more than 100 confirmed cases from 15 different countries where there is no endemic transmission of the virus in animals. Reported cases have no established travel links to endemic areas and based on current information cases have mainly, but not exclusively been identified amongst men who have sex with men. The clade identified in these cases is the less severe West African clade.

Monkeypox virus can be transmitted to a person upon contact with the virus from an animal, human, or materials contaminated with the virus. Person-to-person transmission of the virus is through close contact (i.e. prolonged face to face contact, kissing). Entry of the virus is through broken skin, respiratory tract, or the mucous membranes (eyes, nose, or mouth). In the current outbreak, cases of possible transmission through sexual contact have been noted, but are not confirmed.

WHO case definitions for the current outbreak in non-endemic countries

Suspected case

- A person of the any age presenting with an unexpected rash with one or more of the following signs or symptoms since 15 March 2022:

One of the following:

- Headache
- Fever
- Lymphadenopathy
- Myalgia
- Weakness
- Backpain

- For which the common causes of the acute rash, do not explain the clinical picture, including: Varicella Zoster, Measles, Zika, Dengue, Chikungunya, herpes simplex, primary or secondary Syphilis, Chancroid, LGV, Molluscum Contagiosum, Bacterial skin infections, disseminated Cryptococcosis and allergic reactions.

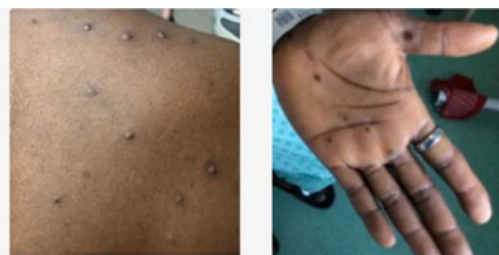AND

One of the following:

- An epidemiological link (direct physical contact with a confirmed case of Monkeypox)
- Travel history to a Monkeypox endemic area in the last 21 days
- Multiple anonymous sexual partners in the last 21 days
- Has a positive Orthopoxvirus serology result in the absence of the previous smallpox vaccination

3, Babatunde Jose street
Off Adetokunbo Ademola Street
Victoria Island, Lagos, Nigeria

Customer Call Centre
0704 653 3040 or
0704 618 1361
clientservices@lancet.com.ng



A rash will appear as red discoloration in the skin. It usually starts on the face, then progresses to the arms and legs, then hands and feet, and then the rest of the body. This phase also lasts one to two days. Papules will develop all over the body as a rash, this also lasts one to two days.

Clinical Management and Infection Prevention and Control in Healthcare Settings

Universal contact and droplet precautions, including hand hygiene, appropriate handling of contaminated laundry and waste and standard surface disinfection should be applied in any facility for outpatient services and all hospitals. If aerosol generating procedures (aspiration of the respiratory tract, bronchoscopy, intubation, CPR) are performed, then standard N95 respirators should be used. A person is contagious from the onset of the rash until all scabs have fallen off.

Treatment is supportive as no specific treatments for Monkeypox are currently available. The antiviral tecovirimat, which is approved in the US for *Orthopoxvirus*-related disease, is not freely available at present. Cidofovir & Brincidofovir may be considered, as both have proven activity against *poxiviruses* in animal and in-vitro studies. Administration of smallpox vaccine can be considered, as both have proven activity against Poxiviruses in animal and in-vitro studies. Administration of smallpox vaccine can be considered for infected individuals and their potential contacts ("ring vaccination" or "cordon sanitaire"). Mass immunization is not indicated. If a person is contagious from the onset of the rash/lesions through the scab stage. Once all scabs have fallen off, a person is no longer contagious.

References:

1. World Health Organization. Monkeypox, [Accessed 29 June 2022.] Available at: <https://www.who.int/news-room/fact-sheets/detail/monkeypox> [Accessed 29 June 2022]
2. World Health Organization *Monkeypox Multi-country Monkeypox outbreak in non-endemic countries* [Accessed 29 June 2022.] Available at: [Multi-country monkeypox outbreak in non-endemic countries \(who.int\)](https://www.who.int/news-room/fact-sheets/detail/monkeypox) [Accessed 29 June 2022]
3. Centers for Disease Control and Prevention. Monkeypox-Information for Clinicians. Available at: [Multi-country monkeypox outbreak in non-endemic countries \(who.int\)](https://www.cdc.gov/mmwr/preview/mmwrhtml/mm6912a1.htm) [Accessed 29 June 2022]
4. National Institute of Communicable Disease. Monkeypox. Available at: <https://www.nicd.ac.za/diseases-a-z-index/monkeypox/> [Accessed 29 June 2022]
5. Centers for Disease Control and Prevention. Available at: <https://wwwnc.cdc.gov/travel/images/monkeypox-nigeria-lg.png> [Accessed 4 July 2022]
6. The conversation. Available at: <https://theconversation.com/monkeypox-is-endemic-in-nigeria-but-surveillance-isnt-what-it-should-be-183711> [Accessed 4 July 2022]
7. Image sourced from the today.com Available at: [Monkeypox Pictures: How to Identify Symptoms of Monkeypox \(https://www.today.com/health/health/monkeypox-pictures-symptoms-rcna30113\)](https://www.today.com/health/health/monkeypox-pictures-symptoms-rcna30113) [Accessed 4 July 2022]